

# Hospital Medicine Pearls for the Internal Medicine Boards - 2021

Michael F. Krug, MD, FACP

Clinical Associate Professor

Associate Residency Program Director

University of Washington School of Medicine

UW Boise Internal Medicine Residency

[krugm@uw.edu](mailto:krugm@uw.edu)

I have no disclosures.



## **Internal Medicine**

Certification Examination Blueprint

All of the topics in this talk were taken directly from stated areas of focus in the ABIM exam blueprint

56yo man has acute onset of dyspnea and chest pain on hospital day #7.

He is being managed for cholangitis related to advanced pancreatic cancer.

Meds: ampicillin/sulbactam, cholecalciferol, sq heparin, megestrol, sertraline

Exam: T 36.8 HR 112 BP 160/95 O2 Sat 93% on 5L NC

CV: tachycardic with regular rhythm

Chest: Clear bilaterally

Ext: no edema

Labs: Platelet count on admission: 212,000. Platelet count today 65,000. Creatinine 1.6 (GFR 50)

Imaging: CTA chest reveals acute pulmonary embolism.

What will you order?

- A. Heparin infusion
- B. Low Molecular Weight Heparin (e.x. enoxaparin)
- C. Direct thrombin inhibitor (e.x. bivalrudin or dabigatran)
- D. IVC filter placement
- E. Mechanical Thrombectomy

What will you order?

A. Heparin infusion

B. Low Molecular Weight Heparin (e.x. enoxaparin)

C. Direct thrombin inhibitor (e.x. bivalrudin or dabigatran)

D. IVC filter placement

E. Mechanical Thrombectomy



**KEY POINT:** Think about Heparin Induced Thrombocytopenia (HIT) in any inpatient with thrombocytopenia or thrombosis

- Typical Platelet count fall is  $>50\%$  with nadir  $>20,000$
- Onset usually between days 5-10 of exposure to heparin (can get it from LMWH also)
- Thrombosis is common but not necessary for diagnosis

# HIT Treatment

- Discontinue heparin
- Full anticoagulation with a non-heparin anticoagulant
  - 53% chance of thrombosis within 30d if not anticoagulated
  - Bivalrudin (IV), argatroban (IV), fondaparinux (SQ), apixaban, rivaroxaban, dabigatran, edoxaban all acceptable



35yo army lieutenant who lives in the barracks presents with the acute onset of headache, neck stiffness, and photophobia.

PMH: none

Allergies: Penicillin – Mom told him he has an allergy. Doesn't know details but doesn't think it was anaphylaxis

Meds: metformin

Exam: T 38.5 HR 105 BP 126/76

Gen: fatigued and ill appearing

Neuro: alert and oriented, slow to respond to questions, +meningismus, no other neuro deficits on comprehensive exam

CSF analysis: WBC 3,500 cells/microL with 92% PMN. Gram Stain shows gram-negative diplococci.

What would you recommend?

- A. Moxifloxacin
- B. Rifampin
- C. Full dose ceftriaxone
- D. Ceftriaxone via test dose procedure
- E. Pretreatment with glucocorticoid and antihistamine then ceftriaxone at full dose

What would you recommend?

A. Moxifloxacin

B. Rifampin

C. Full dose ceftriaxone

D. Ceftriaxone via test dose procedure

E. Pretreatment with glucocorticoid and antihistamine then ceftriaxone at full dose

# Penicillin “Allergy”

- Reported by 10% of patients
- ~1% (10% of those who report PCN allergy) have actual IgE mediated allergy

Among those with true IgE mediated allergy:

<10% cross reactivity with cephalosporins

<1% cross reactivity with carbapenems

Skin Testing is a great option to delineate when available



# Risk Stratify Penicillin Allergy based on reaction history

## SERIOUS REACTIONS

IgE mediated reaction:

Hives/urticaria  
anaphylaxis  
angioedema  
wheezing

Delayed Reaction (types II-IV)

Stevens-Johnson/TEN  
DRESS  
Serum Sickness/Hemolytic anemia



- AVOID Penicillin
- Test Dose Procedure for Cephalosporin or Carbapenem if has IgE rxn history (must avoid if delayed rxn history)

## LOW RISK OF IGE REACTION

Maculopapular Rash  
Unknown Historical Reaction



- 3<sup>rd</sup> or 4<sup>th</sup> gen cephalosporin OK
- Test dose for PCN

## NOT ALLERGIC

Nausea, Diarrhea, Dizziness, Yeast Vaginitis,  
etc.



- OK to give PCN

72yo man presents with spreading redness on his left shin for the past 2 days. He scraped his shin 4 days ago on the edge of his deck where there was a nail head and frayed wood.

PMH: DM2, HTN, hx peptic ulcer

Meds: insulin, metformin, amlodipine, HCTZ, omeprazole

Exam: T 39.0 HR 115 BP 101/50 RR 16 O2 sat 96% on RA

Gen: uncomfortable, lucid

CV: tachycardic, no murmur

Chest: clear

Skin: 10x10cm area of confluent erythema and induration over left lateral shin and calf, severe pain with palpation

Labs: WBC 18k with 86% PMN, HGB 11, Na 126, BUN 30, Creatinine 1.9, glucose 380, CK 900, CRP 130 mg/L (upper limit normal 20)

You start your patient on IV antibiotics and IV fluids.

What will you do next diagnostically?

- A. Surgical Consult
- B. MRI left shin
- C. Ultrasound left shin
- D. Doppler Ultrasound Left Lower extremity
- E. Tetanus serologies

You start your patient on IV antibiotics and IV fluids.

What will you do next diagnostically?

A. Surgical Consult

B. MRI left shin

C. Ultrasound left shin

D. Doppler Ultrasound Left Lower extremity

E. Tetanus serologies





# Recognize and Treat Necrotizing Soft Tissue Infection

Signs/Symptoms: cellulitis with severe pain +/- crepitus, signs of skin necrosis, rapid onset of sepsis

Epidemiology:

Often affects extremities or perineum (Fournier gangrene). No obvious portal of entry in ~50% of cases.

Treatment: surgical exploration and debridement, IV broad spectrum antibiotics including clindamycin (suppresses toxin production)

72yo man presents with spreading redness on his left shin for the past 2 days. He scraped his shin 4 days ago on the edge of his deck where there was a nail head and frayed wood.

PMH: DM2, HTN, hx peptic ulcer

Meds: insulin, metformin, amlodipine, HCTZ, omeprazole

Exam: T 39.0 HR 115 BP 101/50 RR 16 O2 sat 96% on RA

Gen: uncomfortable, lucid

CV: tachycardic, no murmur

Chest: clear

Skin: 10x10cm area of confluent erythema and induration over left lateral shin and calf, severe pain with palpation

Labs: WBC 18k with 86% PMN, HGB 11, Na 126, BUN 30, Creatinine 1.9, glucose 380, CK 900, CRP 190 mg/L (upper limit normal 20)

44yo woman presents with nausea, vomiting, and confusion. Friend thinks she took “a bunch of pills”

PMH: depression

Home Meds: amitriptyline

Exam: T 36.7 HR 80 BP 135/70 RR 35 O2 Sat 99% on RA

Gen: ill appearing

Neuro/Psych: oriented but otherwise confused with odd affect, normal reflexes, no clonus

Labs:

ABG pH 7.47 pCO<sub>2</sub> 23 pO<sub>2</sub> 90

Na 135, K 4, Cl 100, HCO<sub>3</sub> 17, BUN 12, Creat 0.9, Gluc 90, Anion Gap 18, AST/ALT 35/41, AlkP 80, Tbili 0.8, albumin 4

ECG: normal sinus rhythms with normal intervals

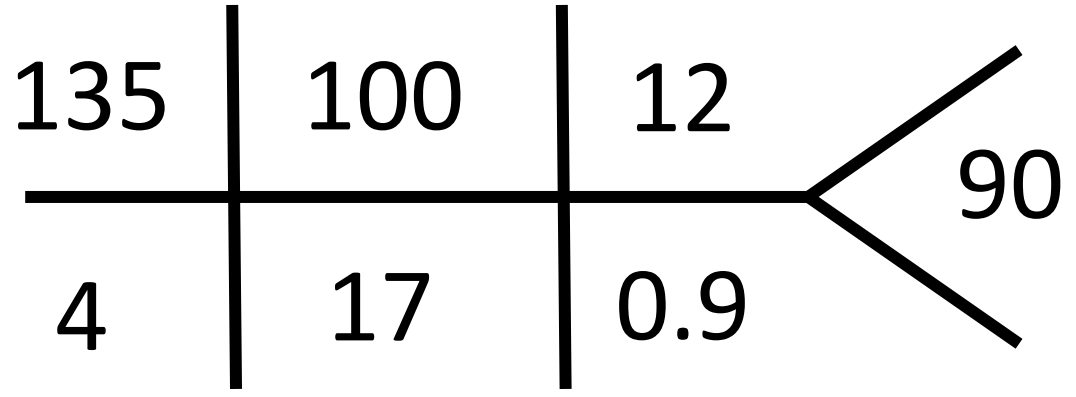
What is your diagnosis?

- A. Tricyclic antidepressant overdose
- B. Serotonin syndrome
- C. Anticholinergic overdose
- D. Salicylate overdose
- E. Acetaminophen overdose

What is your diagnosis?

- A. Tricyclic antidepressant overdose
- B. Serotonin syndrome
- C. Anticholinergic overdose
- D. Salicylate overdose
- E. Acetaminophen overdose

ABG pH 7.47 pCO2 23 pO2 90





Salicylate (aspirin) Poisoning usually leads to a primary respiratory alkalosis with an anion gap metabolic acidosis

Symptoms include **tinnitus**, nausea, and vomiting

Dx with serum salicylate level

Rx: sodium bicarbonate, hemodialysis

What is your diagnosis?

Serotonin syndrome ->AMS plus clonus, tremor, or hypertonia

Anticholinergic overdose ->mad as a hatter, dry as a bone, red as a beet, blind as a bat (mydriasis), hot as a hare, full as a flask

Salicylate overdose ->resp alkalosis + AG metabolic acidosis, tinnitus

Acetaminophen overdose ->hepatic injury

Tricyclic antidepressant overdose ->anticholinergic sx and cardiac conduction abnormalities



75yo man with a chronic nonhealing diabetic foot wound that is worsening despite wound care. He denies fever or chills.

PMH: DM2 with neuropathy and nephropathy, no recent infections

Exam: T 36.7 HR 62 BP 135/70 RR 12

Gen: no acute distress

Foot: chronic left lateral 5th toe ulcer with open tract which probes to bony surface, small ring of surrounding erythema, no purulence noted

Labs: CRP and ESR elevated, WBC count normal, creatinine 1.5

Imaging: MRI suggests osteomyelitis of left 5<sup>th</sup> toe

Micro: wound swab with 3+ Meth Sensitive Staph Aureus sensitive to vancomycin, cefazolin, TMP/SMx. Blood cultures with no growth.

What would you recommend?

- A. Negative Pressure wound therapy (“wound VAC”)
- B. Surgical debridement or removal of toe
- C. IV vancomycin and piperacillin/tazobactam for 2 weeks
- D. IV cefazolin for 2 weeks
- E. PO TMP/SMX for 6 weeks

What would you recommend?

A. Negative Pressure wound therapy (“wound VAC”)

B. Surgical debridement or removal of toe

C. IV vancomycin and piperacillin/tazobactam for 2 weeks

D. IV cefazolin for 2 weeks

E. PO TMP/SMX for 6 weeks

# Non-Hematogenous Osteomyelitis

(contiguous spread of infection to bone, or direct inoculation from trauma)



Diagnosis, cultures, and treatments are all ideally

surgical



Gold standard diagnosis: bone biopsy

Gold standard culture: bone culture from biopsy

Gold standard treatment: debridement and removal of infected source

\*Antibiotics are ideally an adjunct to surgical treatment

\*Wound swabs do not correlate well with bone cultures

# Hematogenous Osteomyelitis

(bloodstream infection seeds bone)

Treatment: IV antibiotics. Surgery is rarely needed.

73yo woman presents for pre-op clearance for knee replacement. She denies dyspnea or chest pain. She is able to climb 2 flights of stairs and do housework like mopping floors and raking leaves. She can only walk 2 blocks due to knee pain.

PMH: CAD with MI and CABG in 2007, History of Stroke in 2014, Type 2 Diabetes for 17 years, Hypertension, Obesity

Meds: aspirin, insulin glargine and aspart, metformin, atorvastatin, carvedilol, lisinopril, furosemide, gabapentin

Exam: T 37.3 HR 65 BP 115/78

Gen: well appearing obese woman in NAD

CV: RRR no murmur, no edema

Chest: CTAB

ECG with sinus bradycardia, no ischemic changes

What would you recommend?

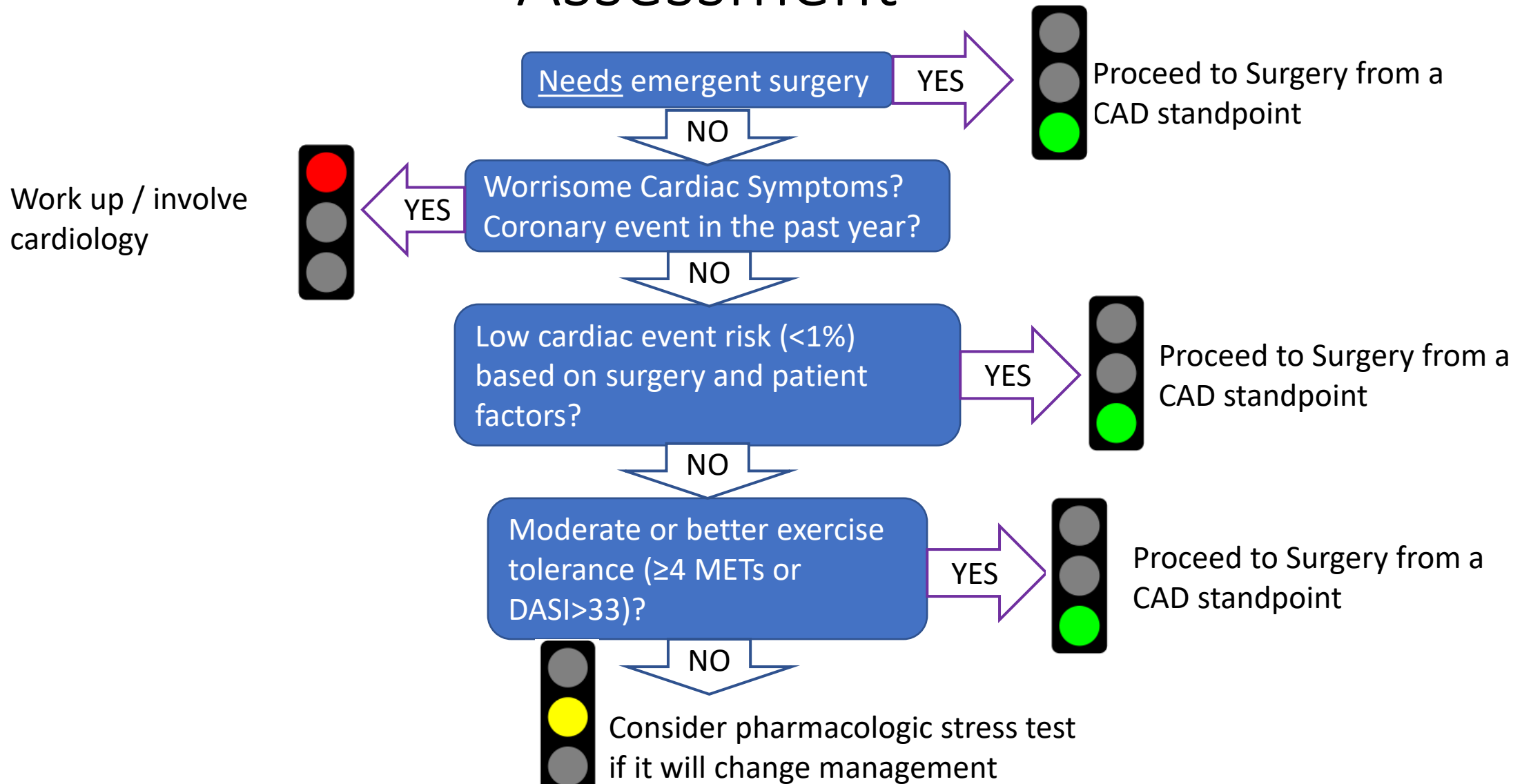
- A. Echocardiogram
- B. Treadmill/Bike ECG stress test
- C. Radionucleotide Nuclear Medicine Stress Test
- D. Cardiology Consult
- E. No further cardiac testing needed

What would you recommend?

- A. Echocardiogram
- B. Treadmill/Bike ECG stress test
- C. Radionucleotide Nuclear Medicine Stress Test
- D. Cardiology Consult
- E. No further cardiac testing needed



# Pre-Op Ischemic Cardiac Disease Risk Assessment



Do not order pre op cardiac stress test unless:

-worrisome symptoms

(angina) that you would work up anyway

OR

-Risk factors and high risk procedure and can't exert at least 4 METs



# What is $\geq 4$ METs?

Walking up 1-2 flights of stairs without stopping.

Walking at 3-4 miles per hour.

Walking uphill 1-2 blocks.

Scrubbing floors/moving furniture/mow yard with push mower.

Bowling or tennis

51yo is post-op day 6 from reconstructive right knee surgery after a traumatic injury to the knee.

You are consulted due to acute kidney injury.

Inpatient Meds: vancomycin, phenytoin, ondansetron, atorvastatin, morphine

Exam: T 37.5 HR 95 BP 145/70

Gen: pleasant, somewhat uncomfortable

MSK: R knee bandaged, + tenderness with movement of knee, + swelling and bruising of R ankle

Labs: sodium 133, potassium 4, chloride 100, bicarb 22, BUN 42, creatinine 1.7.

Urinalysis dipstick with +blood, microscopic urine exam with 3-5 hyaline casts/hpf, 2 WBC/hpf, 0 RBC/hpf

What will you order to help establish the diagnosis?

- A. Urine eosinophils
- B. Urine protein:creatinine ratio
- C. Serum Creatine Kinase level
- D. Serum Vancomycin Level
- E. Doppler Ultrasound of the Renal Arteries

What will you order to help establish the diagnosis?

A. Urine eosinophils

B. Urine protein:creatinine ratio

C. Serum Creatine Kinase level

D. Serum Vancomycin level

E. Doppler Ultrasound of the Renal Arteries

# Rhabdomyolysis

Cause: muscle cell death and release of muscle product into circulation

- Most often due to trauma or muscle compression
- Also commonly due to drugs and meds (especially statins with drug-drug interaction)

Symptoms: myalgias, weakness, red/brown urine (in 50% of cases)

Lab findings:

- Urine dipstick + for “blood” (myoglobin)  
with no or few RBCs on micro exam
- Serum Creatine Kinase (CK) 1,000-100,000 iu/L
- Acute Kidney Injury (due to toxic effect of myoglobin)

	result
pH	7.0
Nitrite	NEG
Occult Blood	2+
Leukocyte Esterase	NEG
Protein	NEG
RBC	0

# Rhabdomyolysis

Treatment:

Aggressive IVF : start with 1-2 L/hr. Goal urine output 250cc/hr.

May need dialysis if AKI has progressed.



23yo woman from Estes Park, CO presents with 1 day of escalating fevers, malaise, and rash. She has no headache, neck ache or photophobia.

PMH: none. She has had all childhood vaccinations.

Meds: None

Exam: T 39.1 HR 135 BP 82/40 RR 24 O2 sat 90% on RA

Gen: ill appearing

CV: tachycardic, no murmur

Chest: clear

Skin: diffuse red macular rash over trunk, upper, and lower extremities including palms and soles

Labs: WBC 16k with 93% PMN, Na 129, BUN 25, Creatinine 1.5, AST/ALT 210/180, Urinalysis normal

CXR: no acute processes

You start your patient on IV antibiotics and IV fluids.

What will you do next diagnostically?

- A. Comprehensive Skin Exam looking for ticks
- B. Lumbar Puncture
- C. Take a sexual history
- D. Pelvic Exam
- E. Echocardiogram

You start your patient on IV antibiotics and IV fluids.

What will you do next diagnostically?

- A. Comprehensive Skin Exam looking for ticks
- B. Lumbar Puncture
- C. Take a sexual history
- D. Pelvic Exam
- E. Echocardiogram

# Staphylococcal Toxic Shock Syndrome

## Signs/Symptoms:

- rapid onset sepsis with multisystem organ failure
- diffuse macular rash resembling sunburn that involves palms and soles

## Epidemiology:

~50% menstrual cause (retained high absorbency tampon commonly)

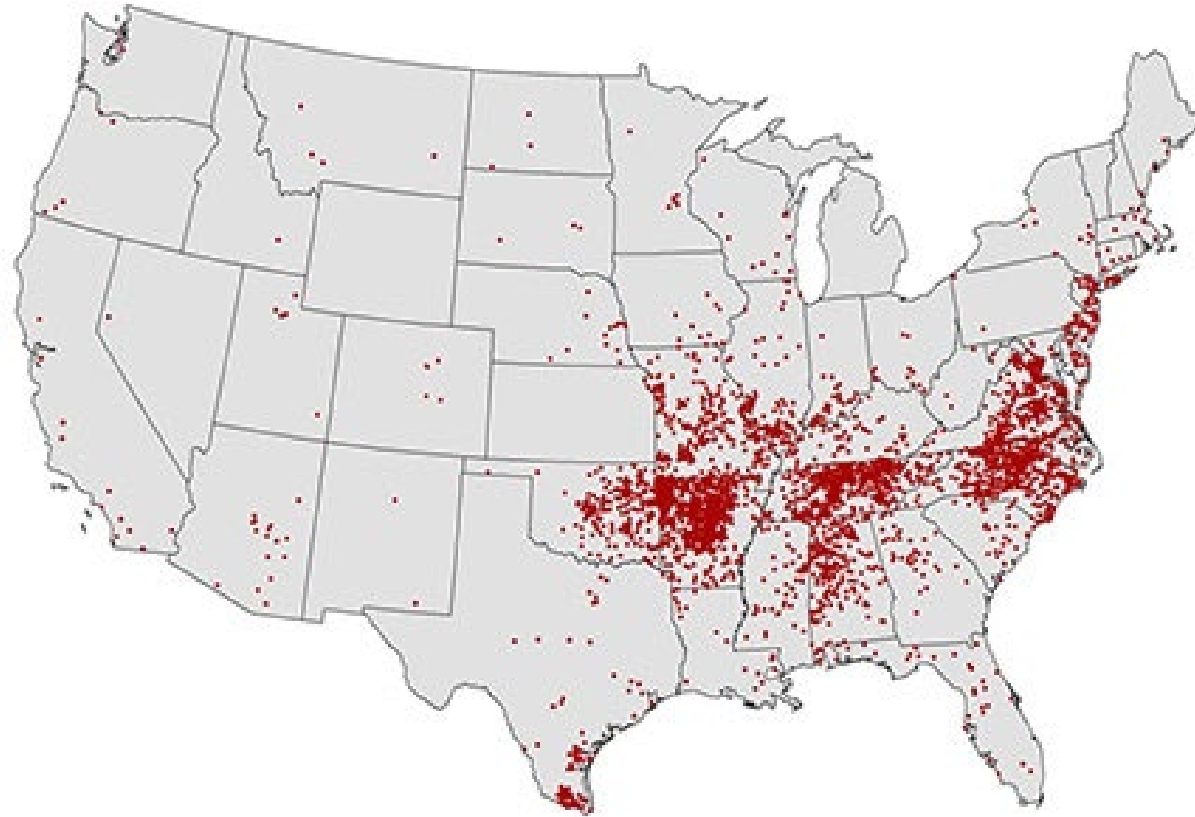
~50% non-menstrual (surgical wound infection, postpartum wound infection, sinus/respiratory infection, skin infection)

Treatment: remove anything from vagina or nose, debride surgical/postpartum wounds, IV abx including clindamycin (suppresses toxin production)

# Rash involving Palms & Soles?

- Rocky Mountain Spotted Fever
- Secondary Syphilis
- Stevens-Johnson Syndrome
- Measles, Mumps, Rubella, Hand Foot & Mouth
- Meningococemia
- Erythema Multiforme
- Toxic Shock Syndrome

# Rocky Mountain Spotted Fever



53yo woman with cystic fibrosis was admitted 8 hours ago with recurrent pneumonia.

You are called because she has since developed agitation and flushing.

PMH: cystic fibrosis, depression, alcohol abuse

Meds: linezolid, piperacillin-tazobactam, promethazine, citalopram, acetaminophen

Exam: T 38.2 HR 122 BP 178/108 RR 16 O2 sat 92% on 2L NC

Gen: agitated

Neuro: answers questions but is disoriented, +dilated pupils bilaterally, +hyper-reflexic at biceps and knees bilaterally, +inducible clonus at ankles

Skin: flushed skin

What is your diagnosis?

- A. Red Man Syndrome
- B. Neuroleptic Malignant Syndrome (NMS)
- C. Malignant Hyperthermia
- D. Serotonin Syndrome
- E. Alcohol Withdrawal



What is your diagnosis?

- A. Red Man Syndrome
- B. Neuroleptic Malignant Syndrome (NMS)
- C. Malignant Hyperthermia
- D. Serotonin Syndrome
- E. Alcohol Withdrawal

# Serotonin Syndrome

Features: clonus and hyperreflexia, can have fever, flushing, tremor, agitation also

Meds:

SSRI, SNRI, TCA, St John's Wort can all predispose to serotonin syndrome through impaired reuptake of serotonin. Usually need a "second hit" such as:

- Stimulant like amphetamines, MDMA
- serotonin agonist like triptan, ergot, buspirone
- MAO inhibitor (impairs metabolism)
- multiple reuptake inhibitors at once – e.x. addition of tramadol, ondansetron

Look out for sneaky MAO-inhibitors: linezolid/zedizolid (antibiotics), rasagiline/selegiline (for Parkinson's disease)

# Toxidromes to Know for the ABIM Boards



Syndrome	Culprit Meds	Clinical Features	Treatment
Serotonin Syndrome	Reuptake inhibitors: SSRI, SNRI, TCA, ondansetron Also look for MAO-i like linezolid, or stimulants	Clonus and hyperreflexia, fever, agitation, flushing, rigidity	Remove offending agents. Supportive Care
Neuroleptic Malignant Syndrome	Haloperidol, fluphenazine, atypical antipsychotics, metoclopramide, promethazine	Rigidity, AMS, fever, dysautonomia	Remove offending agents. Supportive Care
Anticholinergic	Antihistamines, TCAs	“Red as a Beet” “Mad as a Hatter” “Hot as a Hare” “Blind as a Bat”	Remove offending agents. Supportive Care

63yo is admitted with chest pain and dyspnea.

Exam: T 36.5 HR 90 BP 106/56 RR 16

Gen: NAD

CV: RRR no m/g/r

Chest: CTAB

Ext: 2+ pitting edema L leg

Labs: troponin WNL, BNP WNL

ECG: sinus tachycardia

Imaging:

CT angiogram: proximal “saddle” pulmonary emboli from the bifurcation extending into the right and left main pulmonary arteries

Doppler US L leg: large acute L femoral vein DVT

Echocardiogram: mild left ventricular hypertrophy


What will you recommend for treatment?

- A. Systemic Thrombolytic therapy (tPA)
- B. Mechanical Thrombectomy of pulmonary arteries
- C. IV Heparin gtt
- D. IV Heparin gtt plus IVC filter placement
- E. Warfarin therapy

What will you recommend for treatment?

- A. Systemic Thrombolytic therapy (tPA)
- B. Mechanical Thrombectomy of pulmonary arteries
- C. IV Heparin gtt
- D. IV Heparin gtt plus IVC filter placement
- E. Warfarin therapy

# Acute Pulmonary Embolism Treatment



PE Severity	Treatment*
Hemodynamically Unstable (SBP <90 despite IVF)	Systemic thrombolytic therapy (tPA) then anticoag
Intermediate Risk (evidence of Right Ventricle Strain on echo/CTA or +trop or +BNP)	Controversial – either anticoag alone or thrombolytics case by case
Lower Risk	Anticoag alone (LMWH, apixaban, rivaroxaban, heparin gtt)

\*of course must take bleed risk into account

# “Saddle” PE

22% develop hemodynamic instability (with an overall mortality of 5%)



# IVC Filters

AVOID placing them in general unless you “have no choice”

Main indications for IVC filter placement:

1. Proximal leg VTE with contraindication to anticoagulation
2. Proximal leg VTE with progression of VTE despite anticoagulation

74yo with a history of pulmonary embolism 3 years ago is planning for knee replacement surgery

Medications: warfarin, lisinopril

What will you recommend for perioperative anticoagulation?

- A. Stop Warfarin 5-7 days prior to surgery. No bridging
- B. Stop Warfarin 5-7 days prior to surgery. Bridge with LMWH
- C. Place IVC filter then stop Warfarin 5-7 days prior to surgery

74yo with a history of pulmonary embolism 3 years ago is planning for knee replacement surgery

Medications: warfarin, lisinopril

What will you recommend for perioperative anticoagulation?

- A. Stop Warfarin 5-7 days prior to surgery. No bridging
- B. Stop Warfarin 5-7 days prior to surgery. Bridge with LMWH
- C. Place IVC filter then stop Warfarin 5-7 days prior to surgery

# Recommendations on bridging differ by medication class

**Direct Oral Anticoagulants**



**Bridging  
NOT  
Indicated**

**Vitamin K Antagonists  
(warfarin)**



**Occasionally  
Bridge**

# Patients on Warfarin: Bridging Recommendations

	Approximate Annual Thromboembolism Risk	Bridging?
<ul style="list-style-type: none"><li>• AFib with CHA<sub>2</sub>DS<sub>2</sub>-VASc &lt;5</li><li>• Single VTE &gt;12 months prior</li></ul>	<5%	No
<ul style="list-style-type: none"><li>• AFib with CHA<sub>2</sub>DS<sub>2</sub>-Vasc 5+</li><li>• Recurrent VTE, VTE within 3-12 months, or high VTE risk thrombophilia/cancer</li><li>• Bileaflet Mechanical Aortic Valve + TE risk factor</li></ul>	5-10%	Case-by-case
<ul style="list-style-type: none"><li>• VTE, CVA, or TIA within 3 months</li><li>• Mechanical Mitral Valve or ball/disk Aortic Valve</li></ul>	>10%	Yes

38yo with recent IV drug use presents with severe L knee pain.

PMH: IV heroin use including recent daily use, hepatitis C, history of skin abscess

Meds: none

Exam: T 38.9 HR 107 BP 111/65

Gen: uncomfortable, in pain

CV: RRR no murmur

Ext: L knee with small effusion and severe tenderness with ROM movements

Labs: serum WBC 13k

L knee synovial fluid sample: 110,000 cells/mm<sup>3</sup>, 90% PMNs, gram stain with +Gram Positive Cocci

What would you recommend for treatment?

- A. Colchicine
- B. IV Vancomycin
- C. IV Ceftriaxone
- D. IV Vancomycin plus joint drainage
- E. IV Ceftriaxone plus joint drainage

What would you recommend for treatment?

- A. Colchicine
- B. IV Vancomycin
- C. IV Ceftriaxone
- D. IV Vancomycin plus joint drainage
- E. IV Ceftriaxone plus joint drainage



# Septic Arthritis

## Epidemiology/Mechanism:

- most often caused by hematogenous seeding (indwelling catheter infection, endocarditis, IV drug use)
- Can also be caused by extension of infection into joint (cellulitis/osteomyelitis) or direct inoculation (trauma, joint injection)

## Diagnosis:

Severe pain with ROM testing (note that this can also be caused by crystals or blood)

High synovial PMN count (usually 50-150k cells/mm<sup>3</sup>)

Gram Stain, Cultures often positive (not always)

# Septic Arthritis

Treatment:

 Must drain the joint (is basically a closed abscess)

IV antibiotics – vancomycin if GPC, 3<sup>rd</sup>/4<sup>th</sup> gen cephalosporin if GNR

Severe joint pain with any movement of the joint?

**B** blood

**B** bacteria

**C** crystals

# Infectious Source Control

Many niduses of infection require intervention to contain or remove the infectious source

Examples from this talk:


Necrotizing soft tissue infection (debride bacteria and necrotic tissue), osteomyelitis, toxic shock syndrome (remove tampon or debride surgical wound), septic arthritis (drain joint)

Examples not in this talk:

Abscess of any sort (including peri-nephric abscess, empyema, skin, intraabdominal etc), catheter associated UTI (remove catheter), catheter associated blood stream infxn (remove catheter), hardware associated infection

# Answer Key

- 1 – C Direct thrombin inhibitor
- 2 – C 3<sup>rd</sup> generation cephalosporin
- 3 – A Surgical consult
- 4 – D Salicylate overdose
- 5 – B Surgical debridement or removal of toe
- 6 – E No further cardiac testing needed
- 7 – C Serum Creatine Kinase level
- 8 – D Pelvic Exam
- 9 – D Serotonin Syndrome
- 10 – C IV heparin gtt
- 11 – A No Bridging
- 12 – D IV vancomycin and joint drainage



# LIGHTNING ROUND!

No audience response  
system, just murmur  
the answer

63year old presents with fever, agitation, and flushing. On exam he has hyperreflexia and bilateral sustained ankle clonus.

He takes sertraline and was recently started on rasagiline for parkinsons disease.

Diagnosis?

A patient presents with confusion and tinnitus after ingesting 70 aspirin tablets.

What acid-base abnormality will you expect?

How will you treat?



65year old patient is planning to have a partial nephrectomy.

She has no chest pain, dyspnea, or other worrisome symptoms.

She can walk up 3 flights of stairs no problem and mows her  $\frac{1}{4}$  acre yard every week with a push mower.

Does she need a pre-op cardiac stress test?

What patients on DOAC therapy need bridging for surgical procedures?

What patients on warfarin need bridging for surgical procedures?

Urinalysis dipstick shows +blood but microscopic exam shows 0 RBC.

WTH?

What is the gold standard for diagnosis and treatment of non-hematogenous osteomyelitis?

- A) MRI/antibiotics
- B) Surgery/surgery
- C) Depends on who wins the infectious disease vs orthopedic surgery battle that day

What will you think of if a patient has signs of sepsis or severe illness and:

A skin or soft tissue wound

What will you think of if a patient has signs of sepsis or severe illness and:

Is a pre-menopausal woman who has a rash

A patient needs penicillin but has a history of penicillin allergy. The allergy was nausea and dizziness.

What will you do?

What is the main indication for thrombolytic therapy for patients with PE?



A patient needs penicillin but has a history of penicillin allergy. The allergy was angioedema and hives.

What will you do?

A patient needs a 3<sup>rd</sup> generation cephalosporin or a carbapenem but has a penicillin allergy. The allergy was a maculopapular rash with no hives, no anaphylaxis, no angioedema.

Thank you and Good Luck!

[krugm@uw.edu](mailto:krugm@uw.edu)